

Picture Story

A case of congenital insensitivity to pain with anhidrosis

Biplab Maji¹, Partha Pratim Halder², Apurba Ghosh³, Surupa Basu⁴, Priyankar Pal⁵

Sri Lanka Journal of Child Health, 2014; 43(1): 63-64

(Key words: Congenital insensitivity to pain with anhidrosis; CIPA; hereditary sensory and autonomic neuropathy type IV; pain insensitivity; anhidrosis)

Introduction

Congenital insensitivity to pain with anhidrosis (CIPA) is a rare disorder of autosomal recessive inheritance characterised by recurrent unexplained fever, absence of pain sensation with self-mutilating behaviour, absence of sweating and mental retardation since infancy.

Case report

A 4 year old boy, born of a consanguineous marriage, was admitted to our hospital with complaints of recurrent high fever without sweating since birth and failure to thrive. There was a history of a sibling death at age of 7 year with similar complaints. Repeated investigations failed to localise any cause for fever. His body temperature was influenced by environmental temperature and he used to calm down after a bath or cooling with a wet towel. After eruption of teeth he began to chew his fingers and also bit off the tip of the tongue.

On admission, anterior teeth were all absent (figure 1) and evidence of self-mutilation on right thumb and index finger (figure 2) was present. There was a discharging sinus over his left heel. There was lack of response to pain or temperature. But he showed normal tactile sensation, lacrimation, salivation and corneal reflex and no neurodevelopmental delay.

The total white cell count was 18,400/cu mm with a neutrophilic predominance and haemoglobin was 5.4g/dl. Serum ferritin was 8ng/ml. Chest x ray, serum electrolytes, renal function, creatine phosphokinase, uric acid, urinalysis, cerebrospinal fluid, electromyography, nerve conduction velocity, karyotyping and brain MRI were normal.

¹Post Graduate Trainee, ²Resident, ³Professor and Director, ⁴Clinical Biochemist, ⁵Assistant Professor, Institute of Child Health, Kolkata 700017, India

(Received on 15 April 2013; Accepted after revision on 17 May 2013)

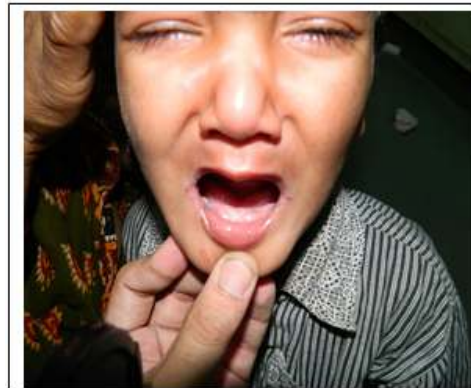


Figure 1: Absence of anterior teeth

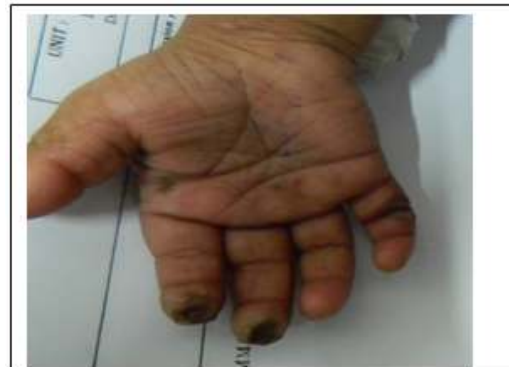

Figure 2: Evidence of self-mutilation

Pilocarpine iontophoresis did not produce any sweat in the child. Skin biopsy and sural nerve biopsy were planned, but not done as CIPA was a clinical diagnosis.

Child again presented to us after 4 months with a bulky, hypermobile left ankle joint on which the child was able to walk properly only with a support. It was diagnosed as a Charcot joint (Figures 3 & 4) and child was discharged on oral antibiotics.

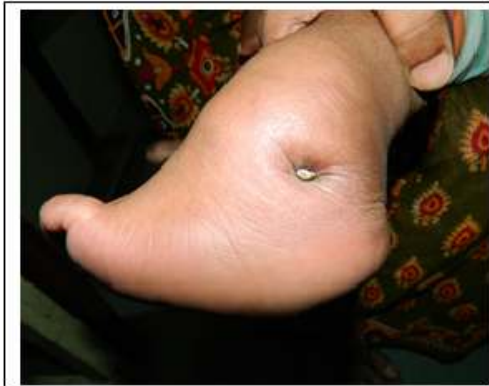

Figure 3: Charcot joint

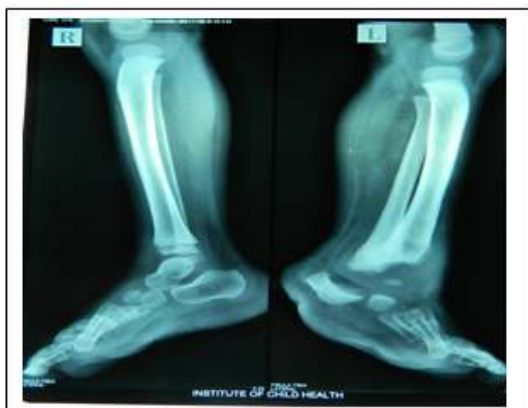

Figure 4: Erosion of bones around left ankle

Discussion

Hereditary sensory and autonomic neuropathy (HSAN) as described by Dua¹ has five types. Type IV is inherited as an autosomal recessive disorder due to lack of maturation of small myelinated and non-myelinated fibres of the peripheral nerves¹. Type IV is also called CIPA.

Ultrastructural and morphometric studies of the peripheral nerves reveal loss of non-myelinated and small myelinated fibres and no innervation to the sweat glands. These features suggest that a defect in the differentiation and migration of neuronal crest elements or possible degradation of the nerve growth factor/neurotrophic tyrosine receptor kinase 1 (NGF/NTRK 1) pathway may be responsible for CIPA².

CIPA usually manifests in early childhood, with self-mutilation. Most of the affected children also show mental retardation. Due to painless injuries,

the bones, joints and soft tissues of the extremities as well as the orbits³, nasal cavities and oral cavity undergo mutilating effects, for which the parents seek medical attention and treatment¹. For the sake of accurate diagnosis, a quantitative sweat test and an intradermal histamine test to check for anhidrosis, along with DNA studies to look for specific mutations can be done. Overheating has in fact been described in the literature to kill more than half of the number of children by CIPA before the age of 3⁴. Thus, parent education is an important component of therapy. Mouth guard and early tooth extraction are used to prevent oral injury⁵. Orthopaedic complications can be prevented by use of special shoe ware, periods of non-weight-bearing, surgical wide debridement and curative osteotomy for deformity.

References

1. Dua T, Sharma J, Singhal T, Arya VB. Hereditary sensory autonomic neuropathy Type IV. *Indian Paediatrics* 2005; **42**:281-4.
2. Mardy S, Miura Y, Endo F, Matsuda I, et al. Congenital insensitivity to pain with anhidrosis: novel mutations in the TRKA (NTRK1) gene encoding a high-affinity receptor for nerve growth factor. *American Journal of Human Genetics* 1999; **64**(6):1570-9.
<http://dx.doi.org/10.1086/302422>
3. Amano S, Fukuoka S, Usui T, Honda N, Ideta R, Ochiai M, et al. Ocular manifestations of congenital insensitivity to pain and -anhidrosis. *American Journal of Ophthalmology* 2006; **141**:472-7.
<http://dx.doi.org/10.1016/j.ajo.2005.10.016>
4. Bar-On E, Weigl D, Parvari R, Katz K, Weitz R, Steinberg T. Congenital Insensitivity to Pain. *Journal of Bone and Joint Surgery British* 2002; **84**:252-7.
<http://dx.doi.org/10.1302/0301620X.84B2.11939>
5. Schalka MM, Corrêa MS, Ciamponi AL. Congenital insensitivity to pain with anhidrosis: A case report with 4 year follow-up. *Oral Surgery Oral Medicine Oral Pathology Oral Radiology and Endodontics* 2006; **101**:769-73
<http://dx.doi.org/10.1016/j.tripleo.2005.07.030>