

# Myocarditis with Cardiac Failure: Initial Manifestation of Systemic Lupus Erythematosus

SUCHI ACHARYA<sup>1</sup>, PRIYANKAR PAL<sup>2</sup>, PRABHAS PRASUN GIRI<sup>3</sup>, AGNISEKHAR SAHA<sup>4</sup>

## ABSTRACT

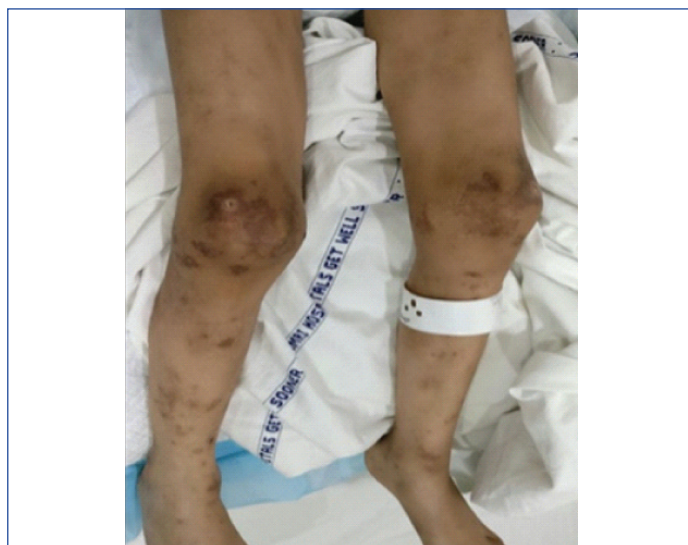Cardiac involvement is very rare in Systemic Lupus Erythematosus (SLE). Pericarditis is the leading cardiovascular manifestation in SLE followed by endocarditis, conduction abnormality, coronary artery disease and myocardial dysfunction. Myocardial dysfunction is most often subclinical, but may rarely progress to ventricular dysfunction, cardiogenic shock or severe congestive heart failure. Myocarditis leading to cardiac failure is a very unusual presentation of childhood lupus. We present a four and half-year-old young boy who presented to us with features of congestive heart failure subsequently diagnosed to be secondary to fulminant lupus myocarditis. Despite intensive management, the child ultimately succumbed. His echocardiography revealed dilated left ventricle with an Ejection Fraction (EF) of 18.2%. A positive titre of p-ANCA was also seen in this case. Although, ANCA positivity has been shown as a bad prognostic marker for lupus nephritis, its association with lupus myocarditis is still unknown. Decongestive measures along with immunosuppressant drugs remain the preferred treatment. This case highlights the protean presentation of SLE in the form of lupus myocarditis leading to congestive heart failure that merits an urgent intervention because of the potentially devastating consequences.

**Keywords:** Cyclophosphamide, Heart failure, Pericarditis

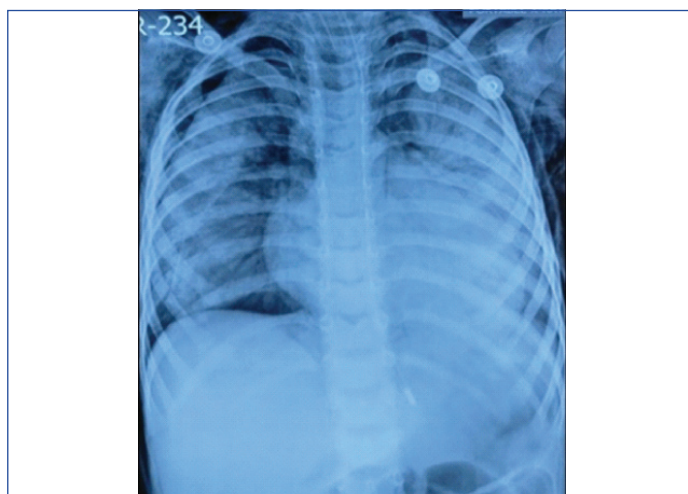
## CASE REPORT

A four and half-year-old boy presented with shortness of breath and lethargy for 15 days. He had grade four dyspnea with orthopnea. He had been losing weight for last two months. One-year back there was a history of purpuric pruritic rash in the upper and lower limb with subsequent generalized spread. Skin biopsy was suggestive of non-specific dermatitis. He was treated with a short course of oral corticosteroid for skin lesions, leaving behind hyperpigmented and desquamated patches all over body. There was no history of any other drug intake except corticosteroid.

On admission, the child was in severe respiratory distress; febrile, tachypneic with respiratory rate of 46/min and heart rate of 164/min. SpO<sub>2</sub> in room air was 84%. He had alopecia and hyperpigmented and desquamated patches all over the body [Table/Fig-1]. Chest auscultation revealed bilateral fine crepitations. Cardiovascular examination revealed raised JVP, S3 gallop with no murmur. Liver was enlarged 3cm below the right subcostal margin, tender, no splenomegaly, and no ascites. Laboratory investigations showed a normal blood count and CRP. Liver function, renal function, creatine kinase and electrolytes were normal. ESR was 78 mm in 1<sup>st</sup> hour. Chest X- Ray (CXR) showed bilateral infiltrates in middle and lower lung fields along with cardiomegaly [Table/Fig-2]. Tuberculosis work up, eye examination and urinalysis were all normal. Blood and urine cultures showed no growth. Electrocardiogram showed sinus tachycardia. Echocardiography revealed thickened and significantly dilated left ventricle with severe systolic dysfunction, EF of 18.2%, dilated left atrium, mild mitral regurgitation, and minimal pericardial effusion. High Resolution Computed Tomography (HRCT) of lungs showed extensive bilateral infiltrate in both lung fields suggestive of acute pneumonitis with mild pericardial effusion. Because of multisystem involvement and without any evidence of an infective aetiology, underlying immunological disease was considered. Immunological work up showed a positive ANA in 1:320, homogenous pattern, and a positive anti ds-DNA. p-ANCA (anti-MPO) was also positive. Serum ACE was normal. C3 was low (75 mg/dL) and C4 was normal. Troponin test was negative.



[Table/Fig-1]: Hyperpigmented and desquamated patches all over the body.



[Table/Fig-2]: Chest X-ray (CXR) showing bilateral infiltrates in middle and lower lung fields along with cardiomegaly.

The child was shifted to Paediatric Intensive Care Unit (PICU) and management for congestive cardiac failure was initiated. Considering a likely diagnosis of lupus myocarditis with congestive heart failure and pneumonitis, pulse methylprednisolone at 30mg/kg/day was started along with hydroxychloroquine. Repeat echocardiography after five days showed minimal improvement with an EF of 26%. After a transient improvement, he again deteriorated with worsening respiratory distress. CXR showed further worsening opacities with extensive bilateral involvement. Repeat sepsis screen was negative and intravenous pulse cyclophosphamide (500mg/m<sup>2</sup>) was given. But he developed air leaks with falling SpO<sub>2</sub> necessitating mechanical ventilation. Antibiotics were upgraded, intercostal drain was given but the child ultimately succumbed on day 17 of admission.

## DISCUSSION

SLE is an autoimmune disorder with a propensity of affecting any organ system including any cardiac component. Cardiac involvement in SLE is primarily localised to the pericardium; though endocardium, myocardium, conduction system of heart and coronary arteries may rarely be affected [1]. Manifestations of lupus myocarditis range from asymptomatic tachycardia to life-threatening congestive heart failure or cardiogenic shock. There are multiple factors that contribute to the pathogenesis of lupus myocarditis like immune injury to the myocardium, coronary vasculitis, valvulopathy, hypertension, and adverse effects of drugs [2,3]. There are very few case reports of clinically apparent lupus myocarditis leading to heart failure as the initial manifestation of SLE in paediatric patients [4,5].

The diagnosis of lupus myocarditis is very challenging because of the high prevalence of viral myocarditis and idiopathic dilated cardiomyopathy in paediatric population. Endomyocardial biopsy is the preferred method to diagnose and to differentiate lupus myocarditis from other causes of myocarditis. But being an invasive procedure with a high risk of mortality and morbidity, diagnosis largely depends on the clinical and echocardiographic findings [6]. Other investigation that may help to diagnose myocarditis include a gallium scan and MRI [7]. Our diagnosis was based on clinical and echocardiography findings in the background of active SLE.

Our patient also had p-ANCA (anti-MPO) positivity. There are studies that have shown positive ANCA association with lupus nephritis usually as a bad prognostic marker [8], but to the author's best of knowledge, no such association is found with cardiac involvement. Whether, the MPO antibodies contributed to the rapidly progressive pneumonitis will also remain unanswered.

There are no specific guidelines for the management of lupus myocarditis. The relative rarity makes controlled trials infeasible and management is usually based on anecdotal reports [7]. There are studies that have demonstrated a favorable response to pulse corticosteroids alone, or in combination with IVIG, cyclophosphamide and other cytotoxic agents such as mycophenolate or azathioprine [9,10]. The child in our case presented with features of dilated cardiomyopathy with intractable heart failure, diagnosed to be secondary to SLE and rapidly succumbed despite of adequate interventions. This shows that lupus being the great mimicker can have any protean presentation including myocarditis and heart failure that can lead to devastating consequences.

## CONCLUSION

We conclude that acute myocarditis with congestive heart failure is a fatal complication of SLE that has potentially devastating consequences including death. So early diagnosis and prompt interventions are needed for rewarding outcome.

## ACKNOWLEDGEMENTS

I am thankful to all faculty members, colleagues and nursing staff of Institute of Child Health, Kolkata for their proper guidance and support.

## REFERENCES

- [1] Maksimowicz-Mckinnon K, Mauzi S. Cardiovascular manifestation of lupus. In: Wallace DJ, Hahn BH, editors. *Dubois' Lupus Erythematosus*. 7<sup>th</sup> edition. Philadelphia, PA: Lippincott Williams and Wilkins; 2007: 663.
- [2] Wijetunga M, Rockson S. Myocarditis in systemic lupus erythematosus. *Am J Med*. 2002;113:419-23.
- [3] Szekanez Z, Shoenfeld Y. Lupus and cardiovascular disease: The facts. *Lupus*. 2006;15S:3-10.
- [4] Patra LB, Mishra AK. Cardiogenic shock as the initial presentation of systemic lupus erythematosus. *Int J Sci Rep*. 2017;3(4):106-07.
- [5] Gurjar M, Singhal S, Poddar B, Baronia AK, Azim A. Acute cardiogenic shock in a girl with systemic lupus erythematosus. *Indian J Crit Care Med*. 2010;14(4):209-11.
- [6] Ansari A, Larson PH, Bates HD. Cardiovascular manifestations of systemic lupus erythematosus: current perspective. *Prog Cardiovasc Dis*. 1985;27:421-34.
- [7] Appenzeller S, Pineau CA, Clarke AE. Acute lupus myocarditis: Clinical features and outcome. *Lupus*. 2011;(20):981-88.
- [8] Jarrot PA, Chiche L, Hervier B, Daniel L, Vuiblet V, Bardin N, et al. Systemic lupus erythematosus and antineutrophil cytoplasmic antibody-associated vasculitis overlap syndrome in patients with biopsy-proven glomerulonephritis. *Medicine (Baltimore)*. 2016;95(22):e3748.
- [9] Naarendorp M, Kerr LD, Khan AS, Omstein MH. Dramatic improvement of left ventricular function after cytotoxic therapy in lupus patient with acute cardiomyopathy: Report of 6 cases. *J Rheumatol*. 1999;26:2257-60.
- [10] Chan YK, Li EK, Tam LS, Chow LT, Ng HK. Intravenous cyclophosphamide improves cardiac dysfunction in lupus myocarditis. *Scan J Rheumatol*. 2003;32:306-08.

### PARTICULARS OF CONTRIBUTORS:

1. Senior Resident, Department of Paediatric Medicine, Institute of Child Health, Kolkata, West Bengal, India.
2. Associate Professor, Department of Paediatric Medicine, Institute of Child Health, Kolkata, West Bengal, India.
3. Assistant Professor, Department of Paediatric Medicine, Institute of Child Health, Kolkata, West Bengal, India.
4. Assistant Professor, Department of Paediatric Medicine, Institute of Child Health, Kolkata, West Bengal, India.

### NAME, ADDRESS, E-MAIL ID OF THE CORRESPONDING AUTHOR:

Dr. Suchi Acharya,  
Address: A-1/5, Diamond Park, Joka, Opposite ESI Joka Hospital, Kolkata-700104, West Bengal, India.  
E-mail: suchi.acharya@yahoo.co.in

Date of Submission: **Sep 17, 2018**

Date of Peer Review: **Oct 30, 2018**

Date of Acceptance: **Nov 14, 2018**

Date of Publishing: **Jan 01, 2019**

FINANCIAL OR OTHER COMPETING INTERESTS: None.